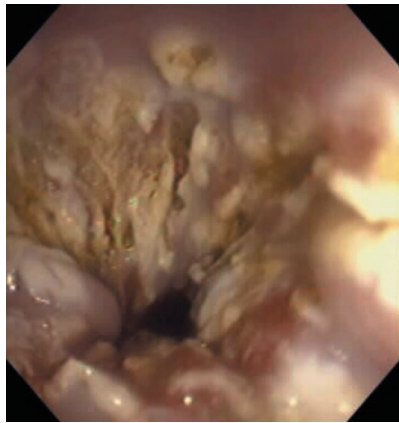

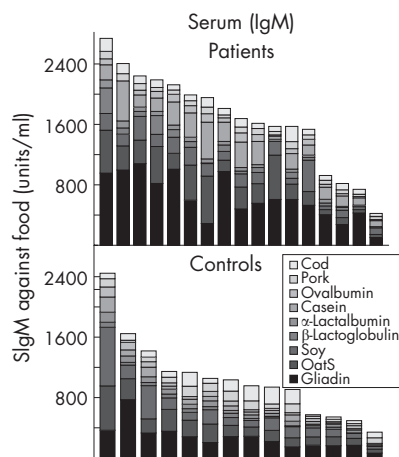


Endoscopic view of the typical coagulation necrosis seen after ablation therapy with argon plasma coagulation.

ABLATION OF BARRETT'S OESOPHAGUS: THE GOOD AND BAD NEWS

With the rising incidence of adenocarcinoma of the oesophagus, a method of eliminating Barrett's oesophagus would be a step forward. The authors randomised 35 patients with Barrett's oesophagus to ablative treatment with either multipolar electrocoagulation or argon beam coagulation. The good news is that both treatments eliminated Barrett's oesophagus at 2 years in approximately 70% of patients, with neither treatment showing any statistical advantage over the other. Adverse events and outcomes were rare. Unfortunately it was not possible to identify risk factors for treatment failure. The bad news is that ablative treatment does not eliminate the need for surveillance as ablation is incomplete in 30% of patients. Repeated biopsies are required of the previous Barrett's area to identify these treatment failures. Furthermore, it is still unknown whether such ablative treatment reduces the risk of subsequent adenocarcinoma. The authors conclude ablative treatment is not yet ready for clinical practice except as palliation for high grade dysplasia or frank cancer in patients unfit for surgery.

See p 1233

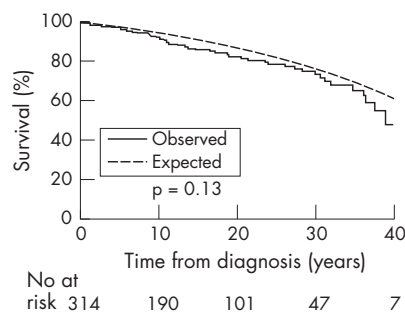


IgM antibodies in jejunal fluid of patients and controls.

INTESTINAL SECRETION OF FOOD ANTIBODIES IN RHEUMATOID ARTHRITIS

Previous authors have suggested that rheumatoid arthritis might involve an abnormal immune reaction to food antigens, but they have assessed serum immunoglobulins. The novelty of the current study is that they examined immunoglobulin (Ig) levels in jejunal fluid. Overall, IgM levels were three- to four-fold increased, with significant increases in antibodies to gliadin, oats, soy, α -lactalbumin, casein, ovalbumin, pork and cod, compared with healthy controls. Five subjects underwent repeat studies after 16 weeks of sulphasalazine and three showed a striking decrease in specific IgM and IgA antibodies. The authors speculate that low gastric acid as a result of disease and/or prescribed drugs may impair degradation of proteins and lead to increased immunoglobulin response to food. Whether this contributes to disease severity remains to be determined. This study focuses attention on the role of the gut immune system in rheumatoid arthritis and suggests novel gastrointestinal approaches to treatment in this disabling condition.

See p 1240



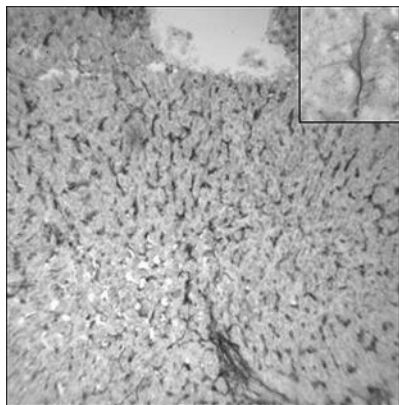
Observed and expected cumulative survival from time of diagnosis in 314 Olmsted County, Minnesota, residents with Crohn's disease diagnosed in 1940-2004 (log rank, $p=0.13$).

SURVIVAL OF PATIENTS WITH INFLAMMATORY BOWEL DISEASE IN OLMSTED COUNTY 1940-2004

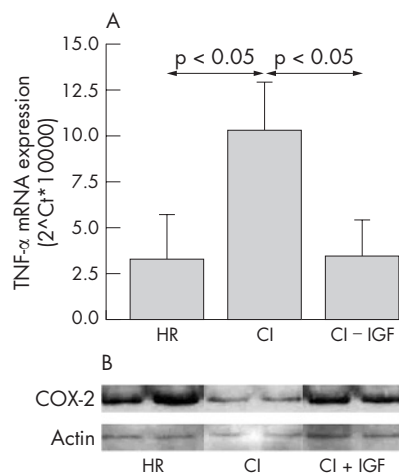
This study used the Mayo Clinic records to calculate survival of 692 Olmsted County residents first diagnosed with inflammatory bowel disease between 1940 and 2001. As the figure shows, overall survival was not significantly different from the general population. There were 56 deaths in patients with Crohn's disease, with an expected of 46. Deaths from gastrointestinal cancer (6) were equalled by deaths from chronic obstructive pulmonary disease (6), and the two combined were equivalent to Crohn's diseases related deaths (11). In the ulcerative colitis cohort there were 62 deaths compared with an expected of 79, 5 of these being due to colorectal cancer, while 12 deaths were attributed to the disease. Notably there was a decreased risk of dying from cardiovascular disease, with 23 deaths compared with an expected 37. There was no apparent effect of immunosuppressants on mortality. Overall, these findings are reassuring but emphasise the importance of persuading our Crohn's patients to stop smoking.

See p 1248

Digest



Synemin expression in HSCs in the normal liver.



(A) TNF α mRNA levels in the ileum of healthy rats (HR), cirrhotic rats treated with vehicle (CI) and cirrhotic rats treated with IGF-1 (CI-IGF). (B) Western blots of COX-2 and β -actin.

HEPATIC STELLATE CELLS EXPRESS SYNEMIN

Hepatic stellate cells (HSC) are subject to intense investigation at present because they play a crucial role in the development of hepatic fibrosis when activated. It is now known that HSC are activated by extracellular matrix molecules such as fibronectin and collagen type I. Intermediate filaments are cytoskeletal elements that play an important role in determining the ability of HSC to withstand mechanical stress. The authors find that synemin binds to the type-III proteins glial fibrillary protein, desmin and vimentin, and are linked to focal adhesions. Synemin is expressed in the quiescent HSC in human and rat liver but its expression is significantly reduced in HSC when activated in cirrhotic livers. The authors propose that synemin expression is a useful marker for inactive HSC.

See p 1276

IMPROVING A LEAKY INTESTINAL BARRIER IN CIRRHOSIS WITH INSULIN-LIKE GROWTH FACTOR-1 (IGF-1)

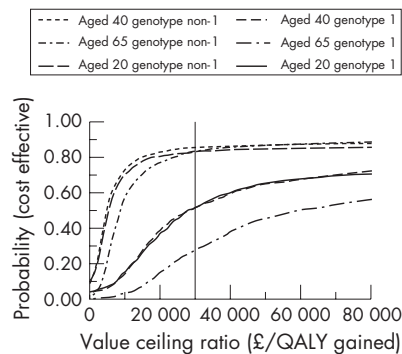
The production of IGF-1, a potent, liver-derived trophic factor is markedly reduced in cirrhosis. The authors hypothesised that exogenous IGF-1 could, by improving intestinal barrier function, reduce endotoxaemia in cirrhosis. Using the carbon tetrachloride-induced cirrhotic rat model they showed the recombinant IGF-1 treated animals showed greater weight gain and reduced liver fibrosis and portal hypertension. There was simultaneously a reduction in villous atrophy and lymphangiectasia and a reduction in intestinal TNF α . IGF-1 compared with vehicle-treated controls increased COX-2 levels, reduced bacterial translocation and to a lesser extent reduced endotoxin levels. Furthermore used in the bile duct ligation model IGF-1 prevented the expected acute increase in gut permeability. Finally, IGF-1 increased transepithelial electrical resistance in isolated cell lines and inhibited the deleterious effect of LPS. These comprehensive studies support clinical trials of IGF-1 to reduce the risks of SBP and other septic complication in liver cirrhosis.

See p 1306

COST EFFECTIVENESS OF TREATMENT OF MILD HEPATITIS C

Approximately 170 million people have Hepatitis C worldwide, which is now the most common indication for liver transplantation. The cost effectiveness of treatment of advanced cases of hepatitis C is well-established but is unknown for mild cases. The authors undertook a cost effectiveness analysis of treatment of mild hepatitis C with either interferon α or peginterferon α combined with ribavirin using a Markov mathematical model. They found that treatment of non-genotype I hepatitis C with either drug regime has a mean cost per quality adjusted life year (QALY) gained of less than £30 000: a threshold frequently considered to define cost effectiveness. The figure shows the probability that treatment was cost effective for differing values of £/QALY gained. Treatment of genotype I hepatitis is only cost effective in patients <65 years of age. If this analysis becomes widely accepted, routine biopsy of patients with hepatitis C will become a thing of the past.

See p 1332



Cost effectiveness acceptability curve of interferon α 2b and ribavirin v no treatment for patients with mild chronic hepatitis C.